

## Median nerve transection following carpal tunnel release with an unusual surgical approach: A case study

Median nerve transection during CTS surgery

Ersen Türkmen, Mehmet Ş. Sakçı, Kadir Ertem  
Department of Orthopaedics and Traumatology, Turgut Ozal Medical Center, Inonu University Medical School, Malatya, Turkey

### Abstract

Multiple mini-invasive surgical approaches have been proposed to reduce the complications accompanied by or emerging from traditional open release of the carpal tunnel. The vertical mini-open blind technique using a short palmar incision distal to the wrist crease has been shown to be safe and easily reproducible with a short recovery period. In the literature, complications involving median nerve injury following carpal tunnel release using the mini-open blind technique through a small incision proximal to the wrist crease are extremely rare or nonexistent. The authors report a case of an incomplete transection of the median nerve following surgery with the mini-invasive (or mini-open) technique through an incision at an unusual site (proximal to the flexion wrist crease).

### Keywords

Median nerve; Carpal tunnel; Mini-open approach

DOI: 10.4328/ACAM.20234 Received: 2020-06-07 Accepted: 2020-07-12 Published Online: 2020-08-16 Printed: 2021-01-01 Ann Clin Anal Med 2021;12(1):111-113  
Corresponding Author: Ersen Türkmen, Department of Orthopaedics and Traumatology, Turgut Ozal Medical Center, İnönü University Faculty of Medicine, Battalgazi, Malatya, 44280, Turkey  
E-mail: dr.ersenturkmen@gmail.com GSM: +90 5300485275 P: +904223410660-5128 F: +90 422 341 07 29  
Corresponding Author ORCID ID: <https://orcid.org/0000-0002-5536-6793>

## Introduction

Carpal tunnel syndrome (CTS) is the most common compressive neuropathy of the upper extremity in which the median nerve becomes compressed in the carpal tunnel due to a variety of reasons. When a regimen of conservative treatment fails to relieve the patient's symptoms, surgical decompression of the median nerve is usually recommended. Numerous approaches for carpal tunnel release have been described that range from one- and two-portal endoscopic approaches to proximal or distal minimally invasive releases to more traditional open approaches. Although complications following the distal minimally invasive (or mini-open) approach have been described, it is generally considered safe and successful. However, reports of median nerve injury following proximal minimally invasive release of the transverse carpal ligament are extremely rare in the literature. We report a case of an incomplete transection of the median nerve following the proximal minimally invasive (or mini-open) technique.

## Case Report

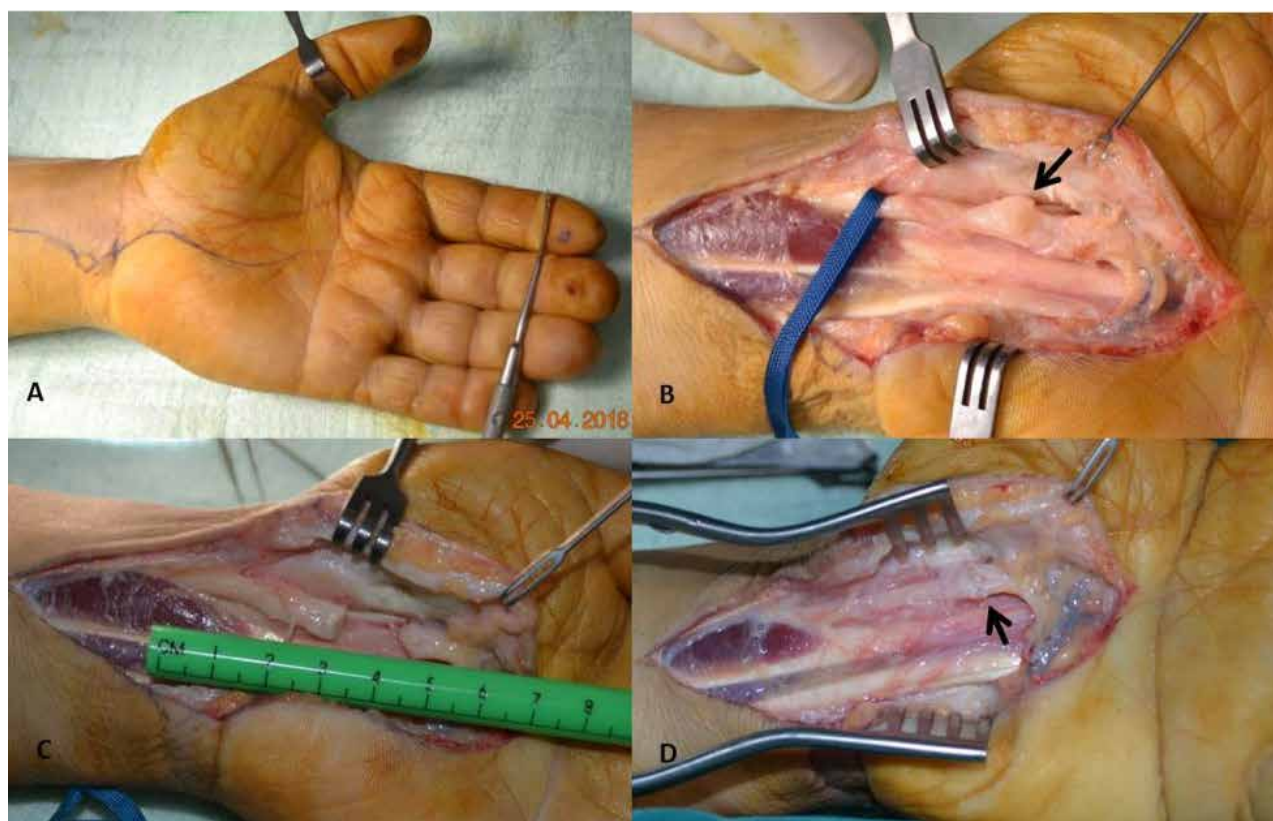
A 41-year-old left-handed male patient was referred to the hand surgery clinic in our hospital for lack of sensation in his left hand following a mini-open carpal tunnel release. He was complaining of numbness, tingling, and night pain affecting both hands but more severe on the left side. He was working as a farmer with repetitive use of both hands. Electrodiagnostic studies revealed mild CTS in the right hand and moderate to severe CTS in the left hand. The patient underwent a mini-open carpal tunnel release through a small incision proximal to the flexion wrist crease. The operation was performed by an orthopedic surgeon at the township hospital.

Postoperatively, the patient reported worsening symptoms with complete anesthesia in the median nerve distribution. He was unable to oppose his left thumb and developed thenar atrophy. Therefore, he was referred to a physiotherapist and received rehabilitation for about two months. During this interval, he had no improvement in his symptoms, so he was referred to the hand surgery clinic of our hospital for an opinion.

During examination, it was noted that the scar of the surgical incision started from the flexion wrist crease and extended 2 cm proximally in a zigzag manner. The patient had thenar atrophy with complete anesthesia in the median nerve distribution. We also noted thermal burns on the tips of the thumb and index and middle fingers that occurred without the patient's awareness because of anesthesia in the median nerve distribution (Figure 1A). He had a negative Tinel's sign, and tactile perception with the two-point discrimination test was impaired. Electromyography was obtained and demonstrated absent sensory and motor latency in the left hand.

The patient underwent revision surgery within two weeks. The operation was performed under axillary regional block anesthesia with the patient in the supine position and his hand on a table. The open approach to the carpal tunnel was used by making a longitudinal incision along the radial border of the ring finger, starting at Kaplan's cardinal line, extending obliquely toward the wrist flexion crease just ulnar to the palmaris longus tendon, and crossing the flexion crease at an oblique angle. Care was taken to veer ulnarly to avoid injury to the palmar cutaneous branch of the median nerve [1] (Figure 1A).

The dissection was carried down subcutaneously to the antebrachial and palmar fascia. The median nerve was then identified and isolated proximally. Next, dissection of the



**Figure 1.** A: Open approach to the carpal tunnel. Note the thermal burns on the tips of the thumb and index and middle fingers, which were encountered due to anesthesia in the distribution of the median nerve B: intraoperative view with the median nerve identified. Neuroma and incomplete transection of the median nerve (arrow) C: intraoperative view demonstrating nerve gap after neuroma resection D: primary end-end repair of the median nerve (arrow)

median nerve was extended distally, and a large neuroma with incomplete transection of the median nerve about 2 cm distal to the wrist crease was found (Figure 1B).

With delicate dissection, the recurrent motor branch of the median nerve to the thenar muscles was identified and protected during the procedure. The neuroma was excised, and the proximal and distal ends of the nerve were trimmed using a sharp blade (Figure 1C). A nerve gap of approximately 15 mm was encountered following resection of the neuroma. However, primary nerve repair with epineural sutures was possible using 8/0 nylon suture material (Figure 1D).

The tourniquet was released. After sufficient hemostasis, a Penrose drain was placed, and the skin was closed with interrupted non absorbable sutures. The wrist was immobilized with a short-arm splint. The day after surgery, the Penrose drain was removed, and the patient was discharged from the hospital. The short-arm splint was removed three weeks after surgery, and physiotherapy was started for active and passive motion. The patient currently demonstrates an advancing Tinel's sign.

## Discussion

CTS is considered the most common pressure neuropathy involving the upper extremity. It requires surgical release of the carpal tunnel when conservative treatment fails. Different surgical techniques can be used depending on the surgeon's preference and the severity of the condition. This ranges from endoscopic release to the mini-invasive or mini-open technique to a more traditional open approach.

Sir James Learmonth was the first to describe open carpal tunnel release (OCTR) in 1933 [1]. This procedure is considered a time-honored method for the treatment of CTS with excellent results and very few reported complications.

In a study comparing open and endoscopic surgeries, Trumble et al. showed that patient satisfaction, functional improvement, and return-to-work duration were much better after the endoscopic method. Scar tenderness was greater in the open surgery group [2].

Murthy et al. suggested that mini-open and extended OCTR offer similar outcomes and that both are safe and effective treatment options for severe CTS [3].

Anbarasan et al. suggested that vertical mini-incision carpal tunnel release at the distal wrist crease can be a safe procedure and achieve satisfactory results that are probably equal or superior to those reported with the conventional or other mini-open methods without the risk of complications and high patient satisfaction [4].

Based on the literature, regardless of the type of surgical approach, most studies indicate that the outcome of carpal tunnel surgery is safe and successful. Unfortunately, little attention has been paid to iatrogenic complications, especially median nerve injury, following mini-open carpal tunnel surgery. Nerve lacerations reported in the literature mainly document the palmar cutaneous branch of the median nerve, which is considered, at least by Louis et al. [5], to be the most frequent complication of OCTR [6- 12].

The most disquieting complications for any surgeon are those in which an unexpected and unfavorable outcome requires

additional intervention to repair the damage. This is the case for our patient who underwent carpal tunnel surgery by an inexperienced surgeon through a mini-open approach at an unusual site (proximal to the flexion wrist crease) with blunt dissection of the transverse carpal ligament, which led to an incomplete transection of the median nerve.

Although release of the median nerve is the goal of treatment, injury to even a few fascicles of the nerve can have devastating consequences for the patient. Therefore, the surgeon should choose the surgical method that offers the best visualization of the median nerve to avoid nerve injury. For this reason, when releasing the transverse carpal ligament, whether performed endoscopically or with the classical open approach, the surgeon should obtain a clear view of the median nerve during the procedure to avoid nerve injury.

We, therefore, recommend that surgeons performing the mini-invasive or mini-open approach are ever mindful of the structures that lie within the carpal tunnel to avoid injury.

## Scientific Responsibility Statement

*The authors declare that they are responsible for the article's scientific content including study design, data collection, analysis and interpretation, writing, some of the main line, or all of the preparation and scientific review of the contents and approval of the final version of the article.*

## Animal and human rights statement

*All procedures performed in this study were in accordance with the ethical standards of the institutional and/or national research committee and with the 1964 Helsinki declaration and its later amendments or comparable ethical standards. No animal or human studies were carried out by the authors for this article.*

## Conflict of interest

*None of the authors received any type of financial support that could be considered potential conflict of interest regarding the manuscript or its submission.*

## References

1. Learmonth JR. The principal of decompression in the treatment of certain diseases of peripheral nerves. *Surg Clin North Am.* 1933; 13:905-13.
2. Shim JH, Roh SY, Kim JS, Lee DC, Ki CH, Yang JW, et al. Normative measurements of grip and pinch strengths of 21st century Korean population. *Arch Plast Surg.* 2013;40(1):52-6.
3. Murthy PG, Goljan P, Mendez G, Jacoby SM, Shin EK, Osterman AL. Mini-open versus extended open release for severe carpal tunnel syndrome. *Hand (N Y).* 2015;10(1):34-9.
4. Anbarasan A, Thevarajah N, Sadagatullah AN. The Functional Outcome of Mini Carpal Tunnel Release. *J Hand Microsurg.* 2017; 9(1):6-10.
5. Louis DS, Greene TL, Noellert RC. Complications of carpal tunnel surgery. *J Neurosurg.* 1985; 62:352-6.
6. Resnick CT, Miller BW. Endoscopic carpal tunnel release using the subligamentous two-portal technique. *Contemp Orthop* 1991; 22(3):269 -77.
7. Murphy RX, Jennings JF, Wukich DK. Major neurovascular complications of endoscopic carpal tunnel release. *J Hand Surg Am.* 1994;19(1):114-18.
8. De Smet L, Fabry G. Transection of the motor branch of the ulnar nerve as a complication of two-portal endoscopic carpal tunnel release: a case report. *J Hand Surg Am.* 1995;20(1):18-19.
9. Gurpinar T, Polat B, Polat AE, Carkci E, Kalyenci AS, Ozturkmen Y. Comparison of open and endoscopic carpal tunnel surgery regarding clinical outcomes, complication and return to daily life: A prospective comparative study. *Pak J Med Sci.* 2019;35(6):1532-7.
10. Williamson ERC, Vasquez Montes D, Melamed E. Multistate Comparison of Cost, Trends, and Complications in Open Versus Endoscopic Carpal Tunnel Release. *Hand (N Y).* 2019; DOI: 10.1177/1558944719837020.
11. Karl JW, Gancarczyk SM, Strauch RJ. Complications of Carpal Tunnel Release. *Orthop Clin North Am.* 2016;47(2):425-33.
12. Tulipan JE, Kim N, Ilyas AM, Matzon JL. Endoscopic Carpal Tunnel Release with and without Sedation. *Plast Reconstr Surg.* 2018;141(3):685-90.

## How to cite this article:

Ersen Türkmen, Mehmet Ş. Sakçı, Kadir Ertem. Median nerve transection following carpal tunnel release with an unusual surgical approach: A case study. *Ann Clin Anal Med* 2021;12(1):111-113